

CASE REPORT

SIMULTANEOUS OCCURANCE OF EMPHYSEMATOUS PYELONEPHRITIS AND EMPHYSEMATOUS CHOLECYSTITIS IN AN UNCONTROLLED TYPE 2 DIABETIC: A CASE REPORT

T. Savitri¹, B. Swetha², D. Sai Raghavendra³, P. Radha⁴

HOW TO CITE THIS ARTICLE:

T. Savitri, B. Swetha, D. Sai Raghavendra, P. Radha. "Simultaneous Occurance of Emphysematous Pyelonephritis and Emphysematous Cholecystitis in an Uncontrolled Type 2 Diabetic: A Case Report". Journal of Evolution of Medical and Dental Sciences 2015; Vol. 4, Issue 31, April 16; Page: 5408-5412, DOI: 10.14260/jemds/2015/791

ABSTRACT: Emphysematous pyelonephritis a life-threatening, fulminant, necrotizing upper urinary tract infection associated with gas within the kidney. Which is a rare condition. Only 1-2 cases per year are encountered in a urological department in the United States. Emphysematous cholecystitis is a variant of acute cholecystitis which is generally caused by gas-forming organisms. This condition develops in approximately 1% of all cases of acute cholecystitis. Compared with typical acute pyelonephritis and typical acute cholecystitis, emphysematous pyelonephritis and emphysematous cholecystitis is associated with much higher rates of morbidity and significantly increased rates of mortality (15-25%). Individually these conditions are less reported, thereby, Simultaneous occurrence of emphysematous pyelonephritis and emphysematous cholecystitis are uncommon and only two cases are reported in literature. As clinical course of both entities are individually severe and life-threatening if not recognized and treated promptly, so in a case of simultaneous occurrence, early diagnosis is to be made and a potentially devastating outcome is to be avoided. We present a case of emphysematous pyelonephritis with emphysematous cholecystitis and pneumoperitoneum in a middle aged uncontrolled diabetic patient and discussed etio-pathogenesis, classification and therapy of these entities.

KEYWORDS: Emphysematous pyelonephritis, Emphysematous cholecystitis, Diabetes mellitus.

INTRODUCTION: Emphysematous pyelonephritis (EPN) is a severe necrotizing infection of the renal parenchyma, it causes gas formation within the collecting system, renal parenchyma, and/or perirenal tissues.⁽¹⁾ Gas in the renal pelvis alone, without parenchymal gas, is often referred to as emphysematous pyelitis. Clinical course of EPN can be severe and life-threatening if not recognized and treated promptly.

Emphysematous cholecystitis (EC) is a rare life-threatening form of acute cholecystitis presenting mainly in patients aged 50-70 years. The ratio of male-female incidence is 3-8/1,⁽¹⁾ while the mortality rate due to EPN and EC is reported as 15% compared to 4% for acute cholecystitis.^(1,2)

Emphysematous pyelonephritis and emphysematous cholecystitis preferentially affects persons with diabetes, the reported frequency reflects how poorly diabetes is controlled in these geographical areas.

Among the bacteria associated with EPN and EC, gas-forming organisms like *Escherichia coli* are isolated in 66% of patients and *Klebsiella* species are reported in 26%. *Proteus*, *Pseudomonas*, and *Streptococcus* species are other organisms found.⁽²⁾

Approximately 50% of patients have diabetes mellitus and suffer other types of associated pathology such as nephropathy and arteriopathy leading to emphysematous cholecystitis through

CASE REPORT

hematogenous dissemination.⁽²⁾ The gas may disseminate to subcutaneous tissue, as well as to the peritoneal and retroperitoneal cavity.⁽³⁾

CASE REPORT: A 58 year old female with non-insulin dependent diabetes mellitus was admitted to our Emergency Department with symptoms in chronological order as tingling, numbness of both upper limbs & lower limbs since 5 years and fever, decreased urine output, abdominal distension since 10 days. Patient is known diabetic since 8 years is on treatment. She discontinued medication since 2 months. Laboratory examination revealed elevated RBS-330mg/dl.

On ultrasound, right kidney contour is difficult to define with dirty shadowing in lower pole and there is 6.4×6.3 cm hypoechoic collection in posterior perirenal space in lower pole. Similar echogenic shadows are noted within gallbladder neck, pericholestatic region, portal triad and in bifurcation of CBD suggestive of pneumobilia.

CECT of abdomen revealed air pockets in neck of gall bladder, biliary tree, lower pole of right kidney and in collection in perinephric space and PCS and in peritoneum.

Based on this information patient was taken for right perirenal abscess drainage and medical management. On follow up sonography decrease in size of perirenal collection with few air pockets and resolution of cholecystitis is noted.

DISCUSSION: Emphysematous pyelonephritis is a severe type of necrotising pyelonephritis. The criteria for defining this condition are presence of gas not only in parenchyma but also in excretory system and perirenal spaces. Differentiating emphysematous pyelitis, a benign condition with gas only in collecting system from emphysematous pyelonephritis is necessary.⁽¹⁾

Emphysematous cholecystitis is less common type (1%) of acute cholecystitis. This condition usually develops in diabetic patients.⁽²⁾

These conditions are seen in both insulin and non-insulin dependent diabetic patients. Diabetic neuropathy and autonomic bladder with decreased urinary emptying favours urinary bladder infections. Arteriopathy leading to vascular compromise of the cystic artery of gallbladder causes ischemia and facilitates the proliferation of gas-forming organisms and bacterial translocation in the devitalized tissue with low oxygen saturation.⁽⁴⁾

Rapidly progressive, life threatening infection with gas-forming organisms coliform bacteria such as E. coli and others and bactericidal bile rendered alkaline, facilitate infection. Emphysematous pyelonephritis can raise possibility of septic seeding of gallbladder wall leading to Emphysematous cholecystitis. Simultaneous occurrence of both EPN and EC are rare in literature. Pneumobilia and Pneumoperitoneum rarely associated with these condition.⁽⁴⁾

Conventional radiograph is sufficient to detect air in renal fossa altering renal outlines and air in or around gall bladder area or in biliary tree.^{(5):}

- Imaging appearance of EP consists of either parenchymal destruction with absence of fluid or presence of streaky or mottled gas or it contains either renal or perirenal fluid and bubbly or loculated gas or collecting system gas.
- CT features of emphysematous pyelonephritis differentiates into two types: In 2000, Huang et al modified the staging proposed by Michaeli et al, as follows:⁽³⁾
- Class 1 - Gas confined to the collecting system.
- Class 2 - Gas confined to the renal parenchyma alone.

CASE REPORT

- Class 3A - Perinephric extension of gas or abscess.
- Class 3B - Extension of gas beyond the Gerota fascia.
- Class 4 - Bilateral EPN or EPN in solitary kidney.
Imaging of EC on ultrasound in 3 stages.⁽⁵⁾

Stage 1: Gas in lumen with echoes in gall bladder.

Stage 2: Gas in wall with wall reflectivity or hyper reflective ring from entire GB circumference.

Stage 3: Gas in pericholestatic tissue and in gall bladder and in wall and outside.

CT demonstrates emphysematous changes in GB wall that are diagnostic includes location and extent of air and fluid collections such as extension into pericholecystic tissues and hepatic ducts.⁽⁶⁾

TREATMENT: Initially patients respond to medical management with intravenous antibiotics, blood glucose correction and fluid replacement. Many with diffuse involvement undergo nephrectomy. Some with focal involvement have been successfully treated with imaging guided percutaneous intervention. Serum levels of creatinine is most reliable predictor of outcome.⁽⁷⁾

Ultrasound guided percutaneous cholecystectomy done may be a temporary measure to control sepsis. Later, if needed cholecystectomy may be done. Post-operatively patient is to be carefully monitored to prevent pseudomembranous enterocolitis.

CONCLUSION: Infection with gas forming organisms and impaired immune protection in diabetics leads to emphysematous pyelonephritis and emphysematous cholecystitis. Rupture of gall bladder and Emphysematous pyelonephritis collection results in pneumoperitoneum.

MDCT is considered the most sensitive and specific imaging modality for identifying gas within the gallbladder and renal fossa. Being a rare morbid condition, arriving to an early prompt diagnosis and staging can be accurately done on MDCT than other modalities.

REFERENCES:

1. Kirchhoff P, Müller V, Petrowsky H, Clavien PA: Fatal emphysematous cholecystitis caused by clostridium perfringens. *Surgery* 2007, 141: 411-2.
2. Moanna A, Bajaj R, Del Rio C: Emphysematous cholecystitis due to Salmonella derby. *Lancet Infect Dis* 2006, 6: 118-20.
3. Catalano O, Nunziata A, Siani A: Emphysematous cholecystitis as a cause of retroperitoneal air. *Emergency Radiology* 2001, 8: 297-298.
4. Emphysematous pyelonephritis and resultant emphysematous cholecystitis secondary to hematogenous dissemination. Lee HM, Jeffrey RB *abdominal imaging* 1995 Mar-Apr; 20 (2): 169-72.
5. Concurrent emphysematous pyelonephritis and emphysematous cholecystitis in type 2 diabetes. *Australian radiology* 2004 Sep; 48 (3): 411-3.
6. Type 2 diabetes, EP and EC *J Assoc physicians India* 2004 Feb 52: 124.
7. Pneumomediastinum as a complication of emphysematous cholecystitis. Delgado-Plasencia L¹, González-García I, Rodríguez-González D, Torres-Monzón A *E BMC Gastroenterol.* 2010 Sep 2; 10: 99. doi: 10.1186/1471-230X-10-99.
8. Emphysematous pyelonephritis in the setting of diabetes mellitus. Gupta P¹, Gupta R, Jandial K, Samotra S, Rana V, Gupta R, Gupta S, Singh J. *J. Assoc Physicians India.* 2011 Feb; 59: 119- 20.

CASE REPORT

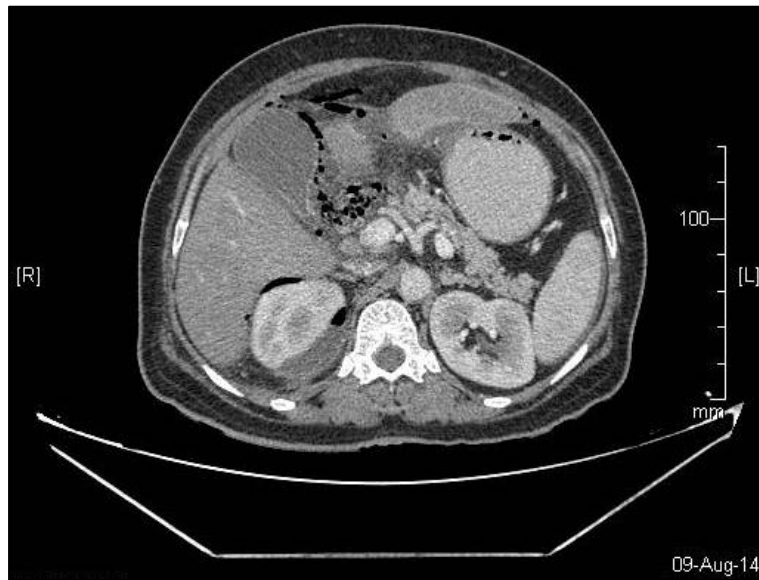


Fig. 1

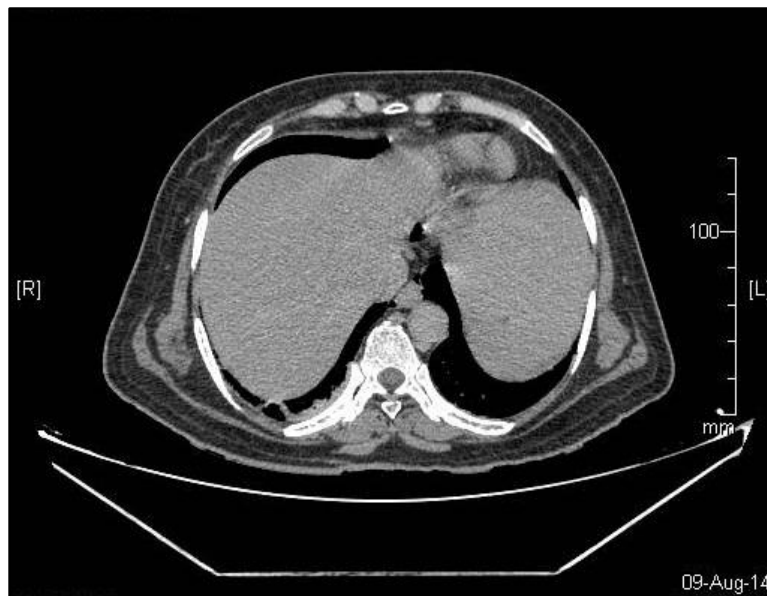

Fig. 2

CASE REPORT

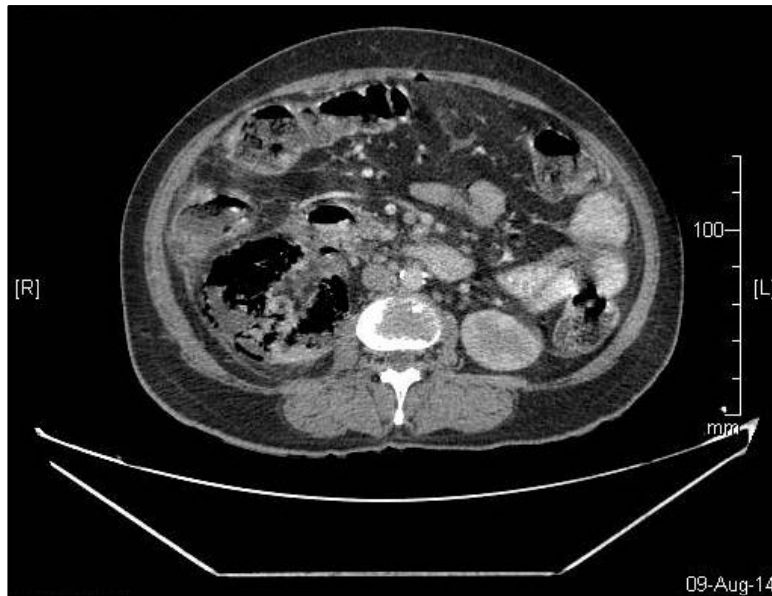

Fig. 3

AUTHORS:

1. T. Savitri
2. B. Swetha
3. D. Sai Raghavendra
4. P. Radha

PARTICULARS OF CONTRIBUTORS:

1. Assistant Professor, Department of Radiodiagnosis, AMC, Visakhapatnam.
2. 2nd Year post Graduate, Department of Radiodiagnosis, AMC, Visakhapatnam.
3. 3rd Year Post Graduate, Department of Radiodiagnosis, AMC, Visakhapatnam.

FINANCIAL OR OTHER

COMPETING INTERESTS: None

4. 3rd Year Post Graduate, Department of Radiodiagnosis, KMC, Manipal.

NAME ADDRESS EMAIL ID OF THE CORRESPONDING AUTHOR:

Dr. T. Savitri
House No. 50-102-6,
Amulya, Near Krishna Mandir,
Seethamadara Ne,
Visakhapatnam-530013.
E-mail: thanukulasavitri@gmail.com

Date of Submission: 20/01/2015.
Date of Peer Review: 21/01/2015.
Date of Acceptance: 06/04/2015.
Date of Publishing: 16/04/2015.